

Transrectal Ultrasound (TRUS) of Prostate

Patient: Brendhan Skeritt, 54 years

Referring Physician: Dr. Shakhi Muhsin

Date: August 18, 2025

Findings


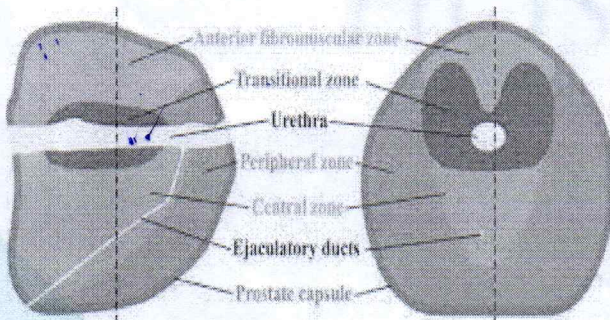
- **Digital Rectal Examination (DRE):** Prostate soft on palpation.
- **Prostate gland:** Normal size and configuration, total volume **25 cc**.
- **Transition zone (TZ):** A **heavily calcified focus** in the right TZ, measuring approximately **14 × 16 mm**.
- **Peripheral and central zones:** No suspicious hypoechoic lesions identified.
- **Seminal vesicles:** Appear normal, symmetric, and not dilated.

Impression

1. **Heavily calcified focus** in the right transition zone (**14 × 16 mm**).
2. **Otherwise, normal prostate gland** (25 cc).
3. **Normal seminal vesicles.**
4. **DRE: soft prostate.**

Recommendation

- No suspicious lesion for malignancy on TRUS.
- Correlation with serum PSA and **continued clinical follow-up advised.**
- No immediate intervention required unless indicated clinically.



Specialist radiologist

Dr OMAR W BAZZAZ

Arabic board of diagnostic radiology

Jordanian board of diagnostic radiology

Koya Rd., Erbil, Kurdistan Region, IRAQ شەقامی کۆیه - هەولێر - هەریمی کوردستان - العراق