

Name:	Hawnas Hamad		
Gender:	female		
DOB:		File No:	
Referring Doctor:	Dr. Ishraq	Date:	27/3/2025

### Obstetrical Ultrasound

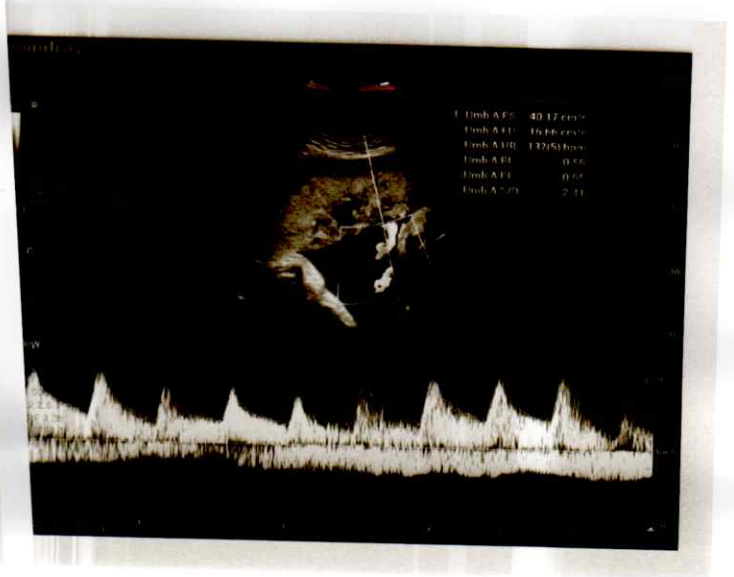
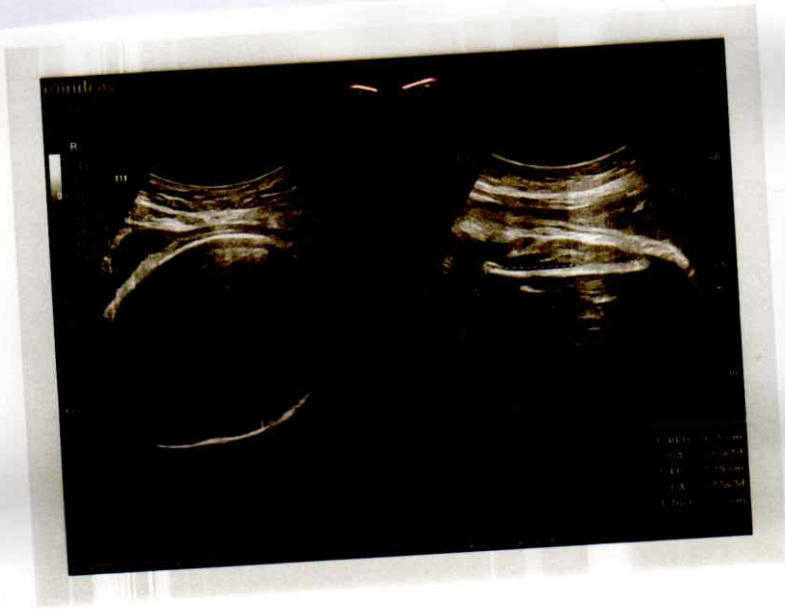#### Report

- Gravid uterus contains single viable fetus
- Fetal heart: positive
- Normal Ant. placenta
- Adequate liquor AFI =12 cm
- Lie: longitudinal
- Presentation :cephalic
- BPD:37 week+ 1 day
- HC:37 week
- FL:37 week +3 day
- EFW = 2905 g
- Normal doppler study of umbilical artery RI = 0.59
- No gross congenital anomaly is seen

#### Conclusion

Regards,

Radiologist:  Dr Hana F. Saber



Gravid uterus contains single fetus  
 Fetal heart: positive  
 Normal Ant. placenta  
 Adequate liquor AFI = 12 cm  
 Lie: longitudinal  
 Presentation: cephalic  
 EFW: 37 week + 1 day  
 HC: 37 week  
 FL: 37 week + 3 day  
 EFW = 3265 g  
 Normal doppler study of umbilical artery RI = 0.25  
 No gross congenital anomaly is seen

Conclusion

Signature: Dr. Mohan S. Suber